BMJ Surgery, Interventions, & Health Technologies

Iterative evaluation of novel access techniques for small bowel obstruction: combining image guided, percutaneous, and endoscopic methods

Kentaro Matsuo,[1,2] Shinya Urakawa,[3] Matthew Symer ,[4] Art Sedrakyan ,[5] Bradley Pua,[6] Jeffrey Milsom [7]

To cite: Matsuo K, Urakawa S, Symer M, *et al*. Iterative evaluation of novel access techniques for small bowel obstruction: combining image guided, percutaneous, and endoscopic methods. *BMJ Surg Interv Health Technologies* 2023;**5**:e000150. doi:10.1136/bmjsit-2022-000150

► Additional supplemental material is published online only. To view, please visit the journal online (http://dx.doi.org/10.1136/bmjsit-2022-000150).

Received 29 April 2022
Accepted 25 April 2023

For numbered affiliations see end of article.

Correspondence to
Dr Matthew Symer; matthew.symer@nyulangone.org

ABSTRACT

Objective To avoid the need for extensive adhesiolysis in patients with small bowel obstruction (SBO). We evaluated the feasibility of using advanced imaging, percutaneous access, and endoscopy as alternative therapies for SBO.

Design Retrospective case series (IDEAL [Idea, Development, Exploration, Assessment, and Long-term Study Collaborative] stages 1 and 2a).

Setting Single tertiary referral center.

Participants Twelve adults with chronic SBO resulting from inflammatory bowel disease, disseminated cancer, radiation, and/or adhesive disease. Participants were included if they underwent one of three novel access procedures. There were no exclusion criteria. The median age of participants was 67.5 years (range 42–81); two-thirds were women; and median American Society of Anesthesiology class was 3.

Interventions All participants underwent one of three novel access methods, followed by wire-guided balloon dilation of a narrowed area of small bowel. These methods combined endoscopic, fluoroscopic, and surgical techniques. The techniques were (1) a purely endoscopic approach aided by an over-the-scope double-balloon device, (2) a combined endoscopic and percutaneous approach, and (3) a cut-down approach.

Main outcome measures Procedural success (defined as successful access to the small bowel and successful balloon dilation of the stenotic area). Secondary outcomes included major complications, recurrence, length of stay, and procedure time.

Results Procedural success was achieved in 10 of 12 patients (83%). At the time of median follow-up of 10 months, recurrence of SBO was observed in two patients. In only one patient, the novel method did not change the treatment plan. No major complications occurred. Conventional operative intervention was avoided in all patients who achieved technical success with one of the novel approaches. The median postprocedure length of hospital stay was 4 days. Median procedure time was 135 min.

Conclusions Novel minimally invasive approaches to SBO represent feasible alternatives to surgical procedures in select patients. Further study should compare these approaches to standard ones as new methods are refined.

WHAT IS ALREADY KNOWN ON THIS TOPIC

⇒ Small bowel obstruction is a common condition leading to surgical intervention with significant morbidity.

WHAT THIS STUDY ADDS

⇒ Combining advanced imaging and novel endoluminal and percutaneous techniques may provide promising alternatives to current surgical methods.

HOW THIS STUDY MIGHT AFFECT RESEARCH, PRACTICE OR POLICY

⇒ Standard operative intervention can be avoided in selected patients via novel approaches, without significant short-term morbidity.

INTRODUCTION

Small bowel obstruction (SBO) is a common intestinal affliction leading to approximately 350 000 admissions and $1.3 billion in expenditures annually in the USA. Surgery for SBO accounts for 5%–10% of all abdominal surgeries.[1]

Traditionally, operative intervention has been advocated for adhesive SBO that does not resolve spontaneously. However, operative management can lead to substantial morbidity in as many as one-third of patients.[2] Since prior surgery is the most common cause of adhesive SBO, there is considerable risk of recurrent obstruction when operating for SBO. In a Swedish study of patients undergoing surgery for SBO, 20% had recurrent SBO in their lifetime. Even higher rates of lifetime recurrence are reported elsewhere.[3] Surgical management of SBO, in its current form, is based on directly accessing the abdominal cavity, manually untwisting or correcting the blockage or creating a diverting stoma. These time honored concepts, while effective, have not evolved substantially for many decades and are clearly associated with substantial

morbidity.[4] In other disciplines, major advances in imaging and endoluminal therapies have been recently leveraged to dramatically alter the approach to diseases such as valvular heart disease and aortic aneurysm.[5 6] It is timely to consider how similar concepts might be applied to the gastrointestinal tract.

For certain benign colorectal anastomotic strictures, the safety and efficacy of endoscopic multidiameter balloon dilation are well established.[7] Moreover, for benign anastomotic strictures after radical gastrectomy for gastric cancer, balloon dilation is considered a primary intervention prior to proceeding with surgical revision.[8] In the small bowel, obstructions due to stricturing Crohn's disease have been successfully treated by double-balloon assisted endoscopic dilation.[9] While promising, this approach is technically challenging and often not possible due to the difficulty of accessing the small bowel by retrograde advancement of the endoscope. There is also a substantial risk of recurrence after balloon dilation.

We have previously shown in preclinical trials and a case report that percutaneous access to the intestine with endoscopic clip closure of the access site is possible.[10] The current series expands on this work, demonstrating that this approach is not only feasible, but that a direct cut-down of the abdominal wall overlying an upstream loop of bowel leading to the obstructed area is feasible as well.

The use of advanced imaging and contrast injection is a critical part of all these methods, helping to locate and treat the obstruction. It is now also possible to achieve three-dimensional (3-D) reconstructive imaging of the intestines in the modern operating room using fusion techniques of cone beam CT fused to preoperative imaging. This allows for accurate pinpointing of the area of abnormality such as the exact location of an obstruction.

Thus, a new approach to minimally invasive intervention for the relief of SBO is now conceivable with a combination of advanced imaging, imaging fusion software, and a set of novel access techniques. Three variations on a method for access to the small bowel are described: purely endoscopic, endoscopic/percutaneous, and cut-down, along with advanced imaging concepts in the operating theatre. These methods mix endoscopic and open surgical techniques to intervene on the small bowel without the need for extensive surgical adhesiolysis. Regardless of the access technique used, a balloon dilation method on the small bowel for the relief of SBO was then attempted. We report on our initial experience and refinement of these methods, as well as short-term incidences of recurrence and major complications. We hypothesized that these methods would be feasible to relieve SBO in select patients. To our knowledge, this is the first report of successful percutaneous access approaches to the bowel for the relief of SBO.

METHODS

We adopted a modified IDEAL methodology for reporting early technique development and refinement (IDEAL stage 1 and early stage 2a). The IDEAL framework is a five-stage conceptual model of surgical innovation development. Adherence to the framework is intended to limit waste in surgical research by improving study design. IDEAL stage 1 interventions are typically proof-of-concept studies. In IDEAL stage 2a, a new idea is refined and iteratively improved until a stable approach is reached. We simultaneously tested three novel approaches using image guidance, with iterative refinement to the technique within each approach. These three methods (purely endoscopic, percutaneous, and direct cut-down) were developed independently of each other but with the common purpose to seek alternatives to standard surgical adhesiolysis or excision. These approaches are used as access methods for lesions of the small bowel. Regardless of the initial approach, once the bowel was accessed, the lesion was then treated with wire-guided balloon dilation or formation of a diverting stoma.

PARTICIPANT SELECTION

Retrospective case series analysis was performed of all adults undergoing attempted combined endoscopic, radiological imaging, and/or percutaneous procedures for SBO at a single tertiary referral center. Procedures were performed by a single experienced surgeon and endoscopist (JM), in conjunction with an attending interventional radiologist (BP), in most cases.

All patients had SBO, and a range of underlying pathologies was included. Patients were included whether their obstruction was due to adhesions, malignancy or radiation enteritis. SBO due to a pathology typically treated with resection or other abdominal operation was excluded, such as those with SBO as a result of hernia, volvulus, gallstone ileus, etc. Ideal candidates for a novel approach presented with a chronic, unifocal obstruction in a location amenable to one of the access methods, particularly in the distal ileum. Short-segment stenoses are likely to be the most amenable to this approach.

All patients were included from the start of when these procedures began to be offered in October 2020 until September 2021. The risks, uncertain benefits, and established alternatives of these procedures were discussed with all patients, and in instances where we could not use these methods, we 'converted' to more traditional surgical methods.

Preoperative evaluation

A standard workup including history and physical and basic laboratory profiles was obtained. Additionally, patients underwent preoperative imaging with contrast-enhanced thin-slice CT (2 mm cuts) using intravenous and oral or rectally administered contrast. Images were reviewed to identify the number, length, and location of strictured areas, potential sites amenable to percutaneous

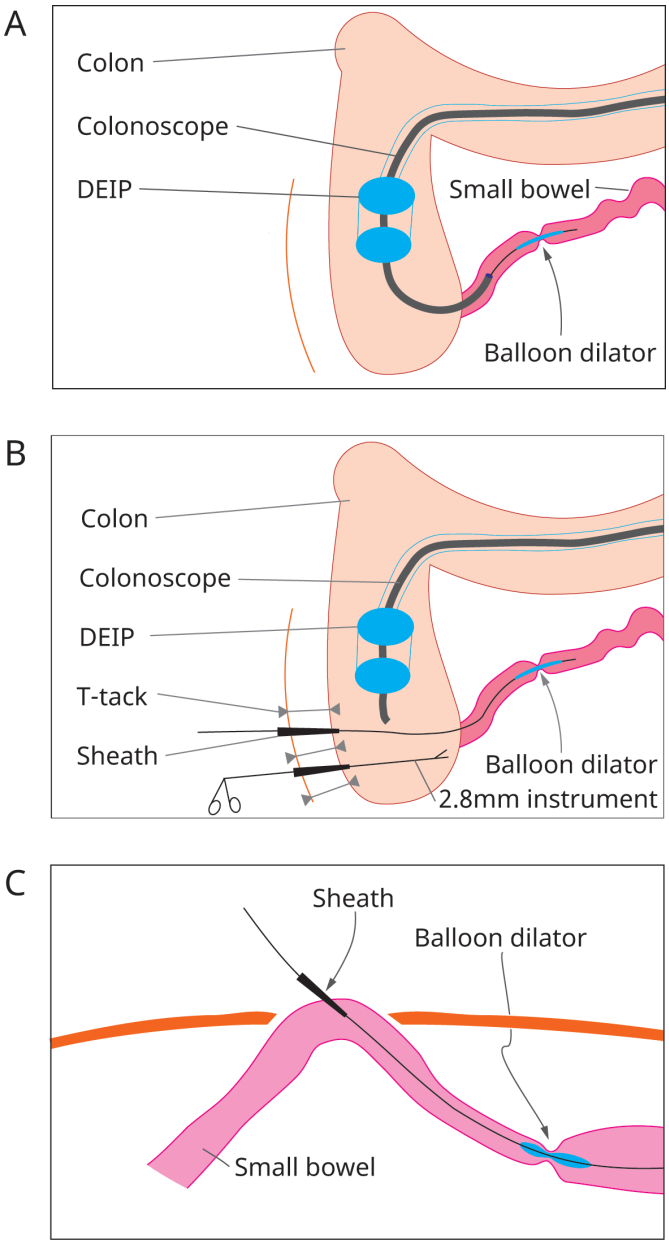

Figure 1 Three approaches to SBO treatment: (A) purely endoscopic, (B) percutaneous, and (C) cut-down. DEIP, double-balloon endoluminal intervention platform.

or cut-down access to those areas, as well as any aberrant anatomy which might alter the treatment plan.

Choice of access technique

One of the three access methods (purely endoscopic, percutaneous or cut-down) was chosen depending on patient factors, and the anatomy was identified through preoperative imaging (figures 1 and 2). Our preference was for a purely endoscopic approach whenever possible. Lesions of the terminal ileum within 20–30 cm of the ileocecal valve are often amenable to this approach (see further). If endoscopy was insufficient to gain access to a strictured area within the distal ileum, we employed percutaneous access for additional assistance. An open cut-down technique to a segment of small bowel adjacent to the obstruction was employed in cases where the target lesion was proximal in the small bowel, if there were concerns for poor wound healing or if there was an anticipated need for proximal intestinal diversion. In all cases, we performed the procedures using a single plane hybrid or fluoroscopic unit (GE Discovery IGS 740, Milwaukee, Wisconsin, USA). Water-soluble contrast (Omnipaque 300) was used endoluminally.

Setting

A hybrid operating room was used. This room is equipped with the full complement of equipment that would be necessary for most open, laparoscopic, endoscopic or interventional radiological procedures. This includes a full suite of open and laparoscopic surgical instrumentation. An endoscopic tower is available with dedicated monitors for simultaneous laparoscopy and endoscopy, as well as a dedicated endoscopic electrosurgical energy source. Additionally, the room is equipped for fluoroscopy and cone-beam CT. Intraoperative helical CT is not available.

Endoscopic access

Under monitored anesthesia care, this procedure was carried out by an experienced endoscopist (JM) using endoscopy (PCF H190, 168 cm) (Olympus Optical Co), combined with either fluoroscopy or cone beam CT. The endoscope was advanced from the colon into the terminal ileum. A double-balloon endoluminal intervention platform (DEIP), a colonoscopic overtube, was deployed to stabilize the scope in the cecum (DiLumen; Lumendi LLC, Westport, Connecticut, USA).[11 12] Inflation of stabilization balloons in the cecum helps to stiffen and stabilize the scope in the right colon, and this additional stability permits easier scope advancement into the small bowel.

Fluoroscopy with either a standard portable unit (GE, model type) or cone beam CT (GE or Siemens) was employed to assist. After advancing the scope through the ileocecal valve to the suspected obstructed area, intraluminal contrast (Omnipaque, Iohexal, 300 mg/mL used at one-half strength or less) was instilled via the scope biopsy channel to characterize the obstruction and confirm its location.

A controlled radial expansion (CRE) wire-guided balloon dilation catheter (CRE Single-Use Wire Guided Balloon Dilator, Boston Scientific) was then advanced to the tip of the scope; the wire was passed through the stricture under radiological control; and dilation was carried out in a standard fashion. (figure 2B) Balloon dilation was performed previously, inside of and below the strictured area over a length of 10–12 cm at least, under direct endoscopic vision, always enhanced by fluoroscopic guidance. Intraluminal contrast injection was used to verify bowel patency after dilation.

Percutaneous access

Initially, we passed an endoscope equipped with a DEIP to the ascending colon. Under direct vision via the

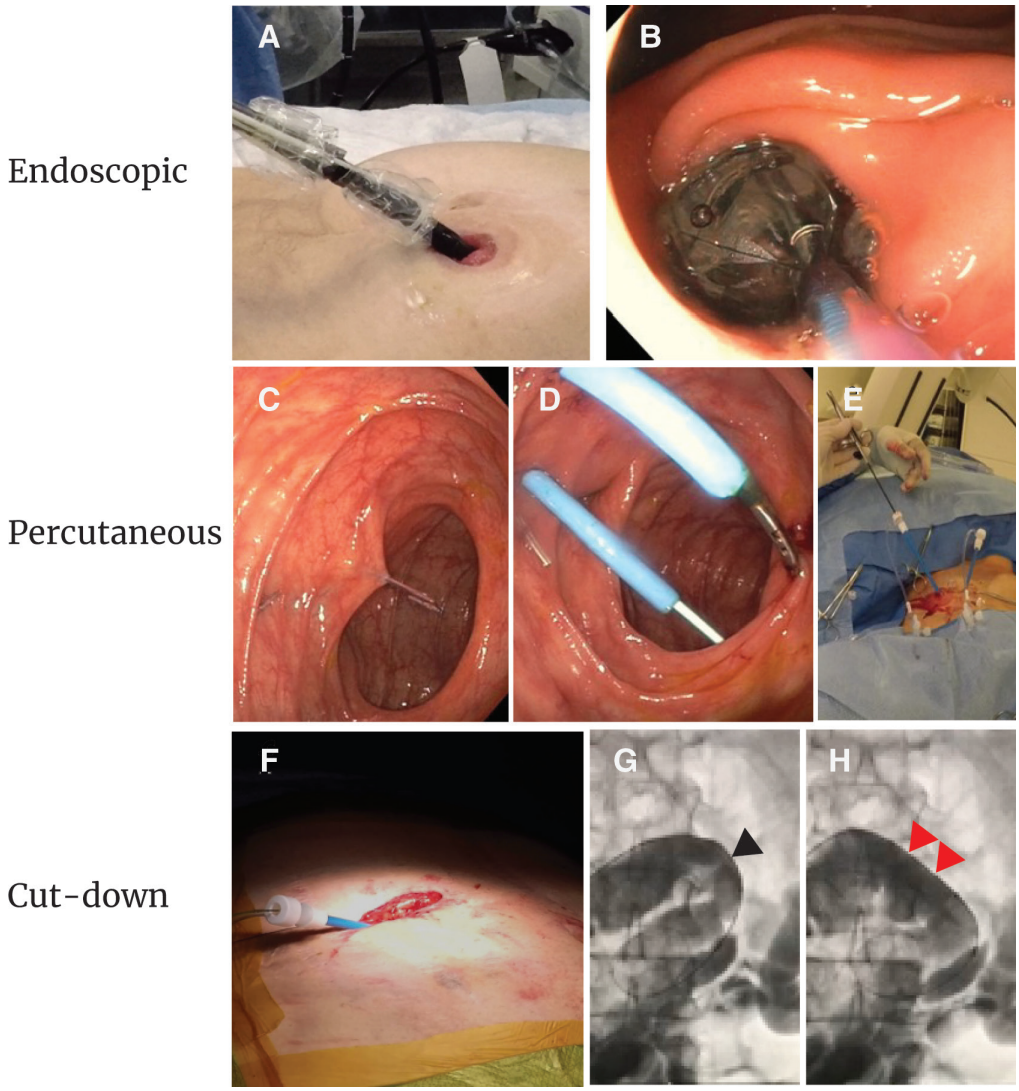

Figure 2 Representative intraoperative images. The endoscopic approach: (A) via an ileostomy using DEIP and (B) wire-guided balloon dilation. Percutaneous approach: (C) T-tack placement, (D) vascular sheath introduction, and (E) intraluminal bowel manipulation with 2.8 mm laparoscopic instrument. Cut-down approach: (F) sheath placement after a small incision has been made, (G) fluoroscopy showing a stricture (black arrowhead) and (H) successful dilation (red arrowheads). DEIP, double-balloon endoluminal intervention platform.

endoscope as well as with fluoroscopic guidance, three T-tacks (Gastrointestinal Anchor Set, Halyard) were placed percutaneously in a triangular fashion via the right flank directly into the lumen of the colon, tacking it to the abdominal wall. The tacks are placed about 3 cm from the other, in the same manner as those used for percutaneous endoscopic gastrostomy tube insertion. Although T-tacks increase stability during the procedure, they can also damage the bowel and require endoscopic access prior to placement. For these reasons, they were employed only during percutaneous cases.

Inside of the triangle of T-tacks, we then passed vascular sheath introducers of variable sizes via Seldinger technique into the colon lumen. The sheath introducer functions as a port site cannula, reducing trauma to the bowel with repeated instrument removal and insertion while also maintaining insufflation. The sheath is sutured to the skin to prevent accidental dislodgement during instrument exchanges. Fluoroscopic guidance with assistance and CO_2 insufflation from the endoscope was used for all phases of lumen cannulation.

A wire-guided CRE dilation balloon passed via an introducer sheath was then used to perform dilation of the strictured area. A variety of instruments can be placed via a second introducer sheath alongside the balloon dilators. For example, angiographic catheters can be placed via 5 Fr sheaths to assist in wire navigation through a stricture. Laparoscopic instruments of 2.8 mm diameter can be placed through 8 Fr sheaths, allowing grasping and manipulation of the ileocecal valve or bowel wall endolumenally. In cases where the lumen cannot be inspected via endoscope, a small disposable bronchoscope (Ambu aScope 4 Broncho Slim, Columbia, Maryland, USA) can also be placed via a 14 Fr sheath. The bronchoscope can help verify successful stenosis dilation and inspect bowel mucosa

for patency and any Crohn's-like inflammation. Due to the larger sheath size needed, a bronchoscope was employed selectively.

At the conclusion of the case, the sheaths were removed, and two to three endoscopic clips (Resolution 360, Boston Scientific) were applied via the colonoscope to close the holes from within the bowel lumen. The colonic mucosa at this time was inspected endoscopically to ensure adequate closure. CO_2 insufflation and contrast instillation were used as a leak test to ensure complete closure of the bowel wall. T-tacks were left in place, covered with sterile dressings, and the cutaneous sutures were removed 1 week post-procedure.

Cut-down access

For cases where the obstructing lesion was in the central portion of the small bowel, more than 20–30 cm from the ileocecal valve, endoscopy was not feasible to assist in endoluminal access. In such cases, a percutaneous/cut-down approach was used. The patient was positioned supine in a hybrid operating room. Preoperative cross-sectional imaging was compared with intraoperative fluoroscopic images. After identifying the targeted loop of bowel radiographically, the abdomen was prepped and draped in sterile fashion, and a small transverse incision (3–5 cm) was made in the abdominal wall approximately 10–15 cm upstream from the target lesion. The incision site could be anywhere on the abdomen, and was chosen to minimize intervening bowel loops or other structures. Ideally, there were also no tight angulations between the cut-down site and the stricture. If there was concern for need for stoma creation, the cut-down site was made in a site amenable to this. The incision was extended down to the posterior rectus sheath, opening the peritoneum. Fluoroscopic images were used to confirm the location of the correct bowel loop and correlate this with preoperative imaging.

The area to be cannulated was then freed on its anterior surface, and a 3–0 Polysorb purse string was placed. Seldinger technique was then used to place an introducer sheath (8–10 Fr) into the small bowel lumen, and the purse string was tightened around it. Fluoroscopy, intraluminal contrast injection, and cone beam CT were used liberally to identify the stenotic area and confirm sheath positioning. Finally, we advanced a series of variable stiffness guidewires through the strictured area and performed sequential balloon dilation under fluoroscopic guidance as described previously.

After successful stenosis treatment and confirmation of bowel patency, the cannula was removed and the purse-string suture was tied. The site was further imbricated with one to two absorbable sutures. In successful cases in which no further treatment was necessary, the abdomen was then closed in layers. In cases that required proximal diversion, a stoma could be brought out directly through the small cut-down opening.

FURTHER TREATMENT

If a stenotic area was refractory to balloon dilation attempts, further treatment using standard surgical methods were used to correct the obstruction. The patient provided consent and was prepared for this in the preoperative discussion and planning.

Outcome measurements

The primary outcome was technical success of the novel access techniques, which we defined as the ability to gain endoluminal access to the small bowel lesion using radiological imaging and one of the endoscopic, percutaneous or cut-down methods, combined with successful balloon dilation of the strictured area. Secondary outcomes were procedure time, in-hospital major complications (including intra-abdominal infection, intestinal perforation, return to the operating room, myocardial infarction, stroke, pneumonia or death), hospital length of stay after treatment and SBO recurrence during the follow-up period. Recurrence was defined as hospitalization, repeat procedure or need for other treatment (laparotomy or laparoscopy) for SBO. The follow-up period was defined as the last outpatient visit or, in the case of recurrence, the time from procedure to recurrence.

Patient and public involvement

Study participants were essential to this research; however, they were not involved in the design, conduct, analysis or reporting of the study. Involvement of members of the public was not sought.

RESULTS

In total, 12 patients were identified who met the inclusion criteria (table 1). The median age of included patients was 68 years (range 42–81 years old); two-thirds were women; and median American Society of Anesthesiologists class was 3. The age and gender of the participants were redacted to maintain confidentiality. The median body mass index was 22.5. Diagnoses leading to SBO included Crohn's disease, endometrial or colorectal cancer, adhesions from prior surgery and radiation enteritis. Most patients had a history of prior abdominal surgery, and many had a lengthy history of multiple prior SBO episodes. Four patients had a history of abdominal malignancy.

Five cases were performed purely endoscopically, three by percutaneous access and four via cut-down. No major complications occurred, even in patients who failed management via one of the novel methods. Exclusively endoscopic access was used for strictures close to the ileocecal valve, at a prior ileocolic anastomosis or upstream from a stoma site. Percutaneous access alone was performed in cases where strictures were located either close to the ileocecal valve or in the terminal ileum but could not be accessed endoscopically alone. Cut-down access was required for cases in the mid-small bowel. A

Table 1 Patient demographics, medical and surgical history

Case	BMI (kg/m^3)	ASA class	Notable history	Prior abdominal treatment	Stricture distance proximal to ileocecal valve	Possible SBO cause
1	23	3	Transient ischaemic attack	Appendectomy (open)	30–40 cm	Adhesive
2	18	2	Endometrial cancer	Pelvic radiation	25 cm	Radiation
3	24	3	Crohn's disease	Total abdominal colectomy	Mid-small bowel	Crohn's disease
4	32	3	Crohn's disease	Total colectomy with ileosigmoid anastomosis for Crohn's disease and ventral hernia repair	Mid-small bowel	Crohn's disease
5	22	2	Crohn's disease	Proctocolectomy with end ileostomy	30 and 40 cm	Crohn's disease
6	18	3	Crohn's disease	Multiple previous operations of large and small bowel	Proximal to an ileocolic anastomosis, in a chain-of-lakes configuration	Crohn's disease
7	18	2	Multiple previous operations	Hernia repair, small bowel resection	30–40 cm	Adhesive
8	23	3	Uterine cancer	Hysterectomy and radiation	Mid-ileum	Radiation
9	25	3	Colon and rectal cancers and endometrial cancer	Pelvic radiation, ileocolic and rectal resections, and end colostomy	20 cm proximal to the ileocolic anastomosis	Adhesive
10	32	3	Morbid obesity	Subtotal colectomy and laparoscopic Roux-en-Y gastric bypass	Mid-small bowel	Adhesive
11	15	4	Heart failure, pHTN, AIDS, ESRD, and congestive liver disease	None	Mid-small bowel	Carcinomatosis
12	21	2	Colon cancer	Right colectomy	6 cm proximal from ileocolic anastomosis	Adhesive

*In some cases, the exact location of the stricture was difficult to determine. Due to the length and tortuosity of the small bowel, a best guess of the stricture location is indicated.
ASA, American Society of Anesthesiologists; BMI, body mass index; ESRD, end-stage renal disease; pHTN, pulmonary hypertension.

variety of technologies and techniques were used within the three access techniques (table 2).

Technical success was achieved in 10 of the 12 cases. The causes of technical failure were unique in the two unsuccessful cases. One case (case 3) began with laparoscopic adhesiolysis, at which time a clear stenotic area was not identified. Percutaneous small bowel access was then obtained and fluoroscopy with intraluminal contrast was performed, but again a clear stenosis could not be identified. Balloon dilation was not performed, and therefore, criteria for technical success were not met. The patient recovered uneventfully after an open enterolysis. A second case (case 6) began with a cut-down, and a chain of multiple long strictures close together was identified. The length of these narrowed areas was too extensive for balloon dilation, so an open small bowel resection was performed. Although balloon dilation was not attempted, radiographic detail from the endoluminal contrast was used to define the extent of resection. Case 11, with advanced carcinomatosis, was converted from a cut-down approach to ileostomy creation. Balloon dilation was performed successfully, but the patient had an additional area of distal stenosis. Given the patient's frailty and numerous comorbid conditions, an ileostomy was judged to be the safest solution. Intraluminal contrast was used to confirm that the location and orientation of the loop ileostomy and that the small bowel was completely open. Radiographic confirmation that the loop was upstream of the obstruction obviated the need for extensive adhesiolysis or a larger incision.

Procedure times were highly variable. The median procedure time was 135 min, with a range from 27 min to 416 min. Percutaneous access cases tended to be the lengthiest. Several cases were particularly long, most commonly due to dense adhesions or difficulty in passing the wire or instruments via the ileocecal valve.

Table 2 Technology and equipment used for each case. Check indicates technology used.

	Case											
Technology used	1	2	3	4	5	6	7	8	9	10	11	12
Cone beam CT		√	√	√	√	√					√	
Fluoroscopy	√	√	√	√	√	√	√	√	√	√	√	√
Colonoscopy+DEIP	√					√	√		√	√		√
Ileoscopy via stoma					√							
Bronchoscope			√	√		√						
Percutaneous introducer sheath		√	√	√		√		√	√		√	
2.8 mm laparoscopic grasper		√										
Controlled radial expansion endoscopic balloon	√				√		√			√		√
Percutaneous transluminal angioplasty balloon		√		√				√	√		√	

Technology was tailored to the needs of each individual case.
√ indicates technology used.
CRE, controlled radial expansion; DEIP, double-balloon endoluminal intervention platform.

Unsuccessful cases or those that required conversion to another method tended to also have prolonged operative times.

All patients were discharged home tolerating at least a liquid diet. The median postoperative length of hospital stay was 4 days (IQR 2.0–6.25 days). The longest stay of 16 days was observed in a patient who failed management via the cut-down approach. A diverting stoma was created; however, the patient had numerous comorbid conditions which required additional management before discharge.

The median follow-up was 10 months (IQR 7–11 months). At the latest follow-up, two patients had recurrent SBO. Case 2 had recurrence 6 months after percutaneous balloon dilation of radiation-induced strictures. This was treated with repeat percutaneous dilation; however, the patient developed a second recurrence 13.5 months from the initial procedure. This was treated with open ileocolic resection and anastomosis. Extensive radiation enteritis and colitis were noted at the time of laparotomy. Case 4 underwent cut-down balloon dilation and developed recurrence at 3 months, treated with repeat cut-down procedure. The patient had a second recurrence 4.5 months after the index procedure that was treated with mini-laparotomy, adhesiolysis, and repeat cut-down balloon dilation. Extensive adhesions were noted at each of the three procedures. No recurrence was seen in these patients after the aforementioned treatments with a follow-up of now over 5 months.

DISCUSSION

Surgical methods (laparoscopic or open) are the gold standard therapy for treating most cases of symptomatic SBOs but are associated with substantial morbidity and a high risk of recurrence. Endoluminal balloon dilation may be a promising alternative but previously has not been feasible for most patients due to the limited access routes available to the small bowel with traditional endoluminal approaches. We have developed endoscopic, percutaneous, and PA/cut-down methods combined with radiological imaging in the operating theatre that permit expanded application of balloon dilation for forms of SBO wherein a narrowing of the lumen has been diagnosed in the preoperative period. These access methods blend endoscopic, radiological, and traditional surgical techniques to guide access to the small bowel. In this study, we report on the characteristics of patients selected for these approaches as well as intraoperative and short-term outcomes. Technical success was achieved in 10 of 12 patients, avoiding the need for surgery to treat SBO. No major complications occurred.

A wealth of information is gained with the extensive cross-sectional imaging that nearly all patients undergo prior to abdominal surgery. Currently, in most cases, this knowledge is used for diagnostic purposes preoperatively but then not actively used in the operating room. In contrast, cardiologists, interventional radiologists and gastroenterologists have more actively used preoperative imaging during their procedures. We are learning that with preoperative imaging, combined with intraoperative imaging using fluoroscopy and cone beam CT, along with endoscopic and percutaneous methods under development, we were able to avoid major surgery in the majority of patients in this cohort.

The anatomical location of the obstruction is an important factor when choosing an approach. In all cases, we recommend intraoperative radiological correlation in concert with one of the access methods. Endoscopic access is our preferred approach whenever feasible as it is the least invasive. Percutaneous access alone can permit intervention on lesions not amenable to purely endoscopic access, but they must nonetheless be relatively close to the ileocecal valve. The PA/cut-down method

is largely free from these constraints and can theoretically be performed anywhere along the small bowel. In practice however, the PA/cut-down approach is limited by anatomical or structural factors. Extensive intra-abdominal scarring and intervening structures such as distended proximal bowel, liver, or transverse colon can limit the areas amenable to percutaneous access. Theoretical disadvantages of the PA/cut-down approach are morbidity from the small abdominal wound and risk of leak from the closed enterotomy. In this small series, we did not identify any wound-related or other complications from either the cut-down or other percutaneous devices such as T-tacks.

Device selection for percutaneous access evolved during the study period. Selection of wires, sheaths, and balloons was based on individual preferences at the start of the study period. Throughout the study period, devices were evaluated and their use evolved. See online supplemental tables 2 and 3 for a listing of devices and interactive changes in their use with each case.

Procedure times were longest with percutaneous access cases. The reasons for these long procedure times were unique to each individual case. In one protracted case, there was considerable difficulty in cannulating the ileocecal valve due to scarring, even with assistance from a percutaneous grasper. Percutaneous cases also required additional steps at the conclusion of the procedure, such as endoscopic clip placement, which add additional time.

In the current configuration, percutaneous access requires initial endoscopic evaluation with an over-the-scope device, followed by percutaneous puncture into the bowel. Insufflation from the endoscope is used to help dilate the bowel up against the anterior abdominal wall for the Seldinger technique sheath insertion, as in percutaneous gastrostomy tube placement. If endoscopic insufflation could be foregone in favor of a purely image-guided approach, this could eliminate some of the procedure time and expand the range of potential therapeutic targets. A variety of equipment and techniques were used across the three approaches (table 2), indicating that there is still considerable evolution of these approaches ongoing. It is likely that future iterative improvements to these approaches will occur.

Even in cases with technical failure of one of the novel methods, the approach still provided valuable information which informed the next steps of the operation. In only one case (case 3) did the percutaneous method not significantly alter the surgical plan. If endoluminal methods are insufficient to relieve the stenosis, the information gained in endoluminal access can limit the extent of further operation required. Radiographic methods, in particular, intraluminal contrast with fluoroscopy or cone beam CT (leading to 3-D images), can verify the orientation of a stoma, confirming that the planned diversion is proximal to the area of concern. This information can greatly limit the dissection necessary for diversion, preventing the need to perform a laparotomy and extensive adhesiolysis.

The recurrence rate after endoscopic balloon dilation of intestinal strictures, when within reach of an endoscope, has historically been relatively high. Small series reporting balloon dilation of colorectal anastomotic strictures typically show excellent efficacy, but many patients require two or more dilation procedures.[13] In the small bowel, other series have reported stricture recurrence rates in other disease processes and locations (eg, Crohn's enteritis) as ranging from 10% to 50%.[14 15] In the short follow-up period reported here, we identified two recurrences. Given the small number of patients involved, there were no clear patterns identifiable. Undoubtedly, stricture location, length and the underlying disease process are important determinants of the risk of recurrence. Further work should clarify the preoperative characteristics of patients prone to recurrence.

This study had several important limitations. All procedures were performed at a single institution by one team, and cases were evaluated retrospectively, limiting the generalizability of our findings. No data were available on patients who were offered one of these novel methods but declined and opted for a different approach. Iterative refinements are ongoing, and these techniques are likely to evolve. Although there were no major complications in the present series, this is an important consideration for future work. Further study with a larger number of patients will be required to examine the safety and efficacy of these approaches, clearly in their early stage of development. The optimal patient population for these treatments remains to be defined.

In a heterogenous cohort of patients with SBO, we demonstrated the feasibility of novel access methods for the relief of obstruction. Just as other 'open' invasive procedures have become uncommon with advancing technology, we believe open surgical access to the small bowel for the treatment of SBO can evolve to far less invasive approaches with the use of a combination of advanced imaging, endoscopy and new tools. The three approaches we have described—purely endoscopic, percutaneous and cut-down, with use of advanced intraoperative imaging methods in the operating theater—challenge the notion that open or laparoscopic surgical methods are the only means of treating SBO. Our approaches seem safe, with no major complications in this small initial series. Short-term clinical success was achieved in 10 of 12 patients. Recurrence/relapse was seen in two patients, and long-term follow-up will be an important future consideration. Our next task, building on this work, is to develop a prospective study using an advanced IDEAL 2a methodology.

Author affiliations
[1]Surgery, Osaka Medical and Pharmaceutical University, Takatsuki, Japan
[2]Surgery, Weill Cornell Medicine, New York, New York, USA
[3]Surgery, Kinan Hospital, Tanabe, Wakayama, Japan
[4]Surgery, NYU Langone Hospital–Long Island, Mineola, New York, USA
[5]Healthcare Polcy and Research, Weill Cornell Medical College, New York, New York, USA
[6]Radiology, Weill Cornell Medicine, New York, New York, USA

[7]Department of Surgery, Weill Cornell Medical College, New York, New York, USA

Twitter Art Sedrakyan @Artsytwits

Contributors All authors contributed to study design, data analysis, manuscript drafting and revision, and gave final approval of the manuscript. JM acted as guarantor.

Funding The authors acknowledge significant technology application support provided by General Electric Healthcare and Leah Kiely. The study was funded by the Center for Minimally Invasive New Technologies.

Competing interests Art Sedrakyan is an Editor-in-Chief of this journal.

Patient consent for publication Not applicable.

Ethics approval The study was approved by the institutional review board (protocol 20–09022637).

Provenance and peer review Not commissioned; externally peer reviewed.

Data availability statement All data relevant to the study are included in the article or uploaded as supplementary information.

ORCID iDs
Matthew Symer http://orcid.org/0000-0003-2722-8155
Art Sedrakyan http://orcid.org/0000-0003-3882-9765
Jeffrey Milsom http://orcid.org/0000-0002-4733-5305

REFERENCES

1 Sikirica V, Bapat B, Candrilli SD, *et al*. The inpatient burden of abdominal and gynecological adhesiolysis in the US. *BMC Surg* 2011;11:13.
2 Quah GS, Eslick GD, Cox MR. Laparoscopic versus open surgery for adhesional small bowel obstruction: a systematic review and meta-analysis of case-control studies. *Surg Endosc* 2019;33:3209–17.
3 Svanes Fevang B-T, Fevang J, Atle Lie S, *et al*. Long-Term prognosis after operation for adhesive small bowel obstruction. *Ann Surg* 2004;240:193–201.
4 Hajibandeh S, Hajibandeh S, Panda N, *et al*. Operative versus non-operative management of adhesive small bowel obstruction: a systematic review and meta-analysis. *International Journal of Surgery* 2017;45:58–66.
5 Endovascular aneurysm repair versus open repair in patients with abdominal aortic aneurysm (EVAR trial 1): randomised controlled trial. *The Lancet* 2005;365:2179–86.
6 Adams DH, Popma JJ, Reardon MJ, *et al*. Transcatheter aortic-valve replacement with a self-expanding prosthesis. *N Engl J Med* 2014;370:1790–8.
7 Chan R-H, Lin S-C, Chen P-C, *et al*. Management of colorectal anastomotic stricture with multidiameter balloon dilation: long-term results. *Tech Coloproctol* 2020;24:1271–6.
8 Lee HJ, Park W, Lee H, *et al*. Endoscopy-guided balloon dilation of benign anastomotic strictures after radical gastrectomy for gastric cancer. *Gut Liver* 2014;8:394–9.
9 Sunada K, Shinozaki S, Nagayama M, *et al*. Long-Term outcomes in patients with small intestinal strictures secondary to Crohn's disease after double-balloon endoscopy-assisted balloon dilation. *Inflamm Bowel Dis* 2016;22:380–6.
10 Urakawa S, Matsuo K, Lowenfeld L, *et al*. Novel percutaneous access to large intestine using a double balloon endolumenal platform for tumor excision: preclinical trials and a case report. *Journal of the American College of Surgeons* 2021;233:e31–2.
11 Sharma S, Momose K, Hara H, *et al*. Facilitating endoscopic submucosal dissection: double balloon endolumenal platform significantly improves dissection time compared with conventional technique (with video). *Surg Endosc* 2019;33:315–21.
12 Sharma SK, Momose K, Sedrakyan A, *et al*. Endoscopic stabilization device evaluation using ideal framework: a quality improvement study. *Int J Surg* 2019;67:S1743-9191(19)30042-1:18–23.:.
13 Araujo SEA, Costa AF. Efficacy and safety of endoscopic balloon dilation of benign anastomotic strictures after oncologic anterior rectal resection: report on 24 cases. *Surg Laparosc Endosc Percutan Tech* 2008;18:565–8.
14 Lopes S, Rodrigues-Pinto E, Andrade P, *et al*. Endoscopic balloon dilation of Crohn's disease strictures-safety, efficacy and clinical impact. *WJG* 2017;23:7397–406.
15 Singh VV, Draganov P, Valentine J. Efficacy and safety of endoscopic balloon dilation of symptomatic upper and lower gastrointestinal Crohn's disease strictures. *J Clin Gastroenterol* 2005;39:284–90.