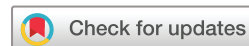

Novel usage of everolimus-eluting coronary stent for intracranial atherosclerotic disease: a technical report and case series

Nangorgo Jean Oumar Coulibaly ¹, Griffin L Ernst,¹ Hussain Shallwani,² Beau Hawkins,³ Usman Baber,³ Hakeem J Shakir¹

To cite: Coulibaly NJO, Ernst GL, Shallwani H, *et al*. Novel usage of everolimus-eluting coronary stent for intracranial atherosclerotic disease: a technical report and case series. *BMJ Surg Interv Health Technologies* 2023;5:e000171. doi:10.1136/bmjst-2022-000171

Received 03 October 2022
Accepted 25 April 2023



© Author(s) (or their employer(s)) 2023. Re-use permitted under CC BY-NC. No commercial re-use. See rights and permissions. Published by BMJ.

¹Department of Neurosurgery, The University of Oklahoma Health Sciences Center, Oklahoma City, Oklahoma, USA
²Neurosurgery, University at Buffalo, State University of New York, Buffalo, New York, USA
³Department of Cardiology, The University of Oklahoma Health Sciences Center, Oklahoma City, Oklahoma, USA

Correspondence to

Dr Hakeem J Shakir;
hakeem-shakir@ouhsc.edu

ABSTRACT

Objectives This report describes the use of an Everolimus-eluting stent (Xience Skypoint stent) for the treatment of medically-refractory ICAD.

Design Retrospective, case-series

Setting In-hospital patients

Participants All patients in this report had a history of stroke secondary to ICAD. All patients failed aggressive medical treatments and had recurrence of symptoms despite anticoagulation or dual-antiplatelet therapy plus a statin. Diagnostic angiogram in each case showed severe vessel stenosis, therefore patients were recommended for intracranial artery stenting.

Main outcome measures Technical feasibility of deploying Xience Skypoint stent for treatment of ICAD.

Results The Xience Skypoint stent was safely and effectively deployed in the vertebral artery (x1) and the internal carotid artery (x2) using trans-ulnar (x1), trans-radial (x1), and trans-femoral (x1) approaches without the use of an intermediate catheter.

Conclusion Second-generation EES such as Xience Skypoint may be utilized for treatment of medically-refractory ICAD. This technical report serves as a proof of concept for further studies analysing long-term safety and efficacy of such stents for treatment of ICAD.

INTRODUCTION

Intracranial atherosclerotic disease (ICAD) is a leading cause of transient ischemic attack (TIA) and acute ischemic stroke.¹ In one study, intracranial plaques and stenotic arteries were present in 62% and 43.2% of patients with brain infarct (BI), respectively. Forty-three percent of patients with BI had a luminal occlusion >30%.² Several clinical trials have been performed to assess the best treatment option for ICAD. These include the Warfarin-Aspirin Symptomatic Intracranial Disease Trial, the Stenting and Aggressive Medical Management for the Prevention of Recurrent Stroke in Intracranial Stenosis (SAMMPRIS) trial, and the Vitesse Intracranial Stent Study for Ischemic Stroke Therapy (VISSIT) trial.³ SAMMPRIS and

WHAT IS ALREADY KNOWN ON THIS TOPIC

⇒ Trials have shown that intracranial stenting using bare-metal stents for intracranial atherosclerotic disease (ICAD) have increased risk of periprocedural strokes compared to maximal medical management

WHAT THIS STUDY ADDS

⇒ This study highlights the technical feasibility of using the Xience Skypoint stent for intracranial stenting.

HOW THIS STUDY MIGHT AFFECT RESEARCH, PRACTICE OR POLICY

⇒ The outcomes of this study can serve as the proof of concept that future trials can lean on to analyze the long-term safety and efficacy of the stent in treating ICAD.

VISSIT clinical trials concluded that aggressive medical management was safer than the Wingspan (balloon expandable) stent, with lower rates of stroke, TIA, and deaths.^{4 5} As a result of those trials, stenting for ICAD is now mainly reserved for severely symptomatic patients with recurrent symptoms despite best medical treatment.

Complications caused by bare metal stents (BMS) fostered the development of other stent systems like the drug-eluting stents (DES). In vertebral artery (VA) stenting, BMS in-stent stenosis rate was reported to range from 10% to 67%.⁶ Developed as a substitute for BMS, first-generation DES like paclitaxel-eluting stent and sirolimus-eluting stent also showed complications such as late stent thrombosis after stopping dual-antiplatelet therapy in percutaneous coronary interventions (PCI).⁷⁻⁹ Subsequently, second-generation DES like everolimus-eluting stent (EES) was developed and showed promise in lowering revascularization and thrombosis risks in patients.^{7 10 11}

The Xience Skypoint EES is a DES used for PCI. The stent is made from medical-grade cobalt chromium and contains a thin layer of a drug called everolimus on its surface that allows for a controlled release of the drug to the vessel walls.¹² Everolimus is a mammalian target of rapamycin inhibitor that reduces tissue growth into the stent.¹³ Considering EES low thrombotic and revascularization risk, we describe our institutional experience in using this stent for intracranial stenting for treatment of ICAD. This study intends to demonstrate the technical nuances and procedural safety of using a coronary drug-eluting stent, the Xience Skypoint (Abbott Park, Illinois, USA), for treatment of ICAD.

METHODS

Patient selection and consent

All patients in this report had a history of stroke secondary to ICAD. All patients failed aggressive medical treatments and had recurrence of symptoms despite anticoagulation or dual-antiplatelet therapy plus a statin. Diagnostic angiogram in each case showed severe vessel stenosis, therefore patients were recommended for intracranial artery stenting. In each case, consent was obtained by explaining to patients the risk of intracranial artery stenting including strokes, intracranial hemorrhage, vascular injuries, and vessel restenosis. Patients were explained that the Wingspan stent is currently the only Food and Drug Administration (FDA)-approved stent for intracranial stenting, however, several nationwide trials have demonstrated its risk for in-stent restenosis and strokes. They were also explained regarding the off-label intracranial use of Xience Skypoint stent as a drug-eluting stent for treatment of ICAD and to prevent future stroke. For the first case, the patient was aware that an interventional cardiologist (BH) would be present in the room to assist with stent deployment. Patients were given the

option of alternative courses and no promises of cure were made.

Data collection

Patient data including age, sex, diagnosis, and postprocedural complications were collected. Procedural and radiological data collected included access site, vessel stented, stent size, number of stents deployed, length of procedure, and antiplatelet therapy post-operation. The primary outcomes assessed were procedure success and periprocedural complications. We retrospectively evaluated all variables using patients' charts.

RESULTS

Procedures

All the procedures were performed by the same endovascular neurosurgeon (HS). No medications were withheld prior to the procedures. In all cases, the Xience stent was deployed using a biaxial system composed of a guide catheter and a coronary guidewire. The 0.014 ASAHI Prowater guidewire (Asahi Intecc, Tokyo, Japan) was exclusively used in each case. In coronary PCI, the ASAHI Prowater was described as highly maneuverable wire with low friction, which facilitates navigation in tortuous vessels and reduces chances of vessel dissections.^{14 15} Details of each individual case are described below. Postprocedure all patients were put under 6 months antiplatelet therapy. Data collected are shown in [table 1](#).

Case 1

An adult patient presented to the emergency department (ED) with the onset of balance difficulties, trouble walking, and worsening of the patient's aphasia and facial droop. The patient has a recent history of VA narrowing and posterior circulation ischemic strokes. CT angiography (CTA) revealed total occlusion of the left VA and

Table 1 Patient, procedural, and radiological data

Case number	1	2	3
Diagnosis	Right vertebral artery stenosis	Right internal carotid artery stenosis	Left supraclinoid internal carotid artery stenosis
Postprocedural complications	RUE hematoma	None	None
Access site	Trans-ulnar	Trans-radial	Trans-femoral
Vessel stented	Vertebral artery	Right ICA	Left ICA
Stent size	4.0×33 mm	4×36 mm	2.25×12 mm
Guide catheter used	Benchmark	RIST	Walrus BGC
Preplasty	Yes	No	No
Postplasty	No	No	No
Number of stents deployed	1	1	1
Length of procedure	48 min	58 min	60 min
Antiplatelet therapy	Aspirin+clopidogrel	Aspirin+clopidogrel	Aspirin+ticagrelor

BGC, Balloon Guide Catheter; ICA, internal carotid stenosis; RUE, right upper extremities.

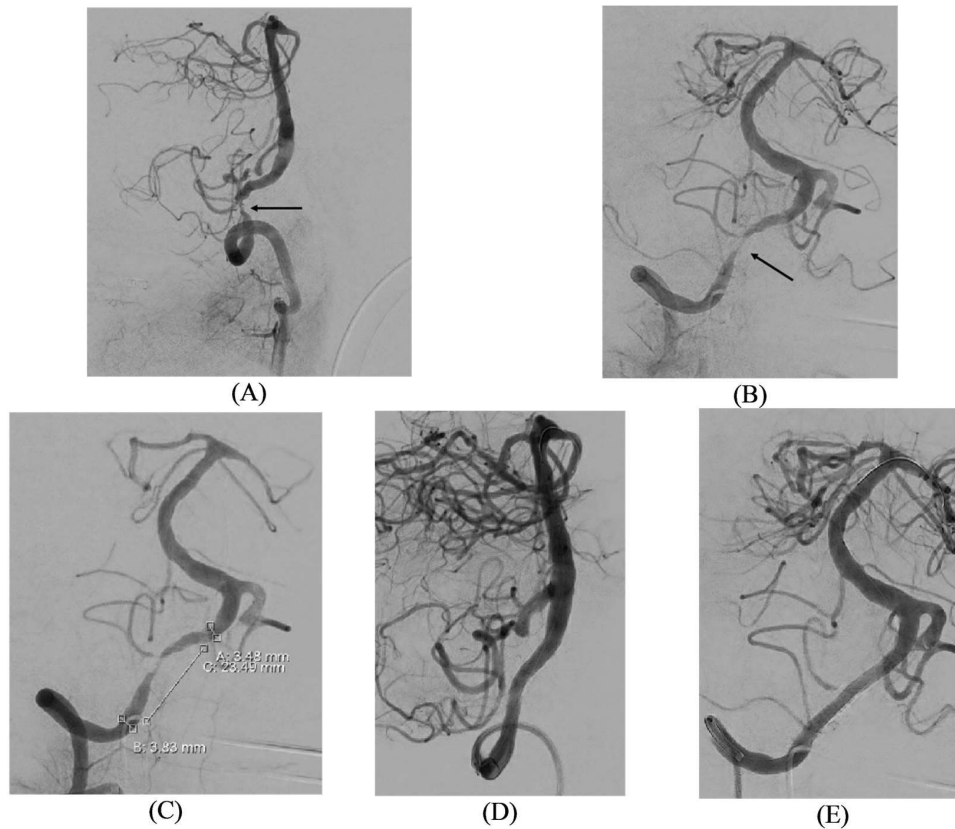


Figure 1 Adult patient with severe narrowing of the right vertebral artery (VA). (A) Lateral view of the right VA. (B) Anterior-posterior (AP) view of the right VA with V4 segment stenosis. (C) AP view of the right VA with measurements for stent placement. (D) Lateral view of the right VA after stent deployment. (E) AP view of the right VA after stent deployment.

severe narrowing of the right VA. Diagnostic angiography confirmed left VA occlusion and revealed intracranial VA atherosclerosis with critical right V4 stenosis and likely chronic distal left VA occlusion (figure 1). The patient was kept under dual antiplatelet therapy (DAPT) (aspirin+clopidogrel) throughout the hospital stay. Two days before the procedure, the patient's platelet function assay test was 8 (180–376 platelet reactivity unit (PRU)), and their platelet count was 104000 (150 000–450 000). The patient underwent a right VA balloon angioplasty and stenting for adequate recanalization.

For this procedure, the patient was placed under general anesthesia. A 6-French slender sheath (Terumo, Somerset, New Jersey, USA) was placed under ultrasound-guided access using a trans-ulnar approach. The Benchmark (Penumbra, Alameda, California, USA) guide catheter was advanced over a Berenstein (Merit OEM, South Jordan, Utah, USA) select catheter and used to select the right VA. The Berenstein select catheter was removed. The Benchmark catheter was advanced into and parked in the V3 segment. A 0.014 ASAHI Prowater guidewire was advanced through the Benchmark catheter and crossed the stenosis into the right PCA. A coronary balloon was advanced, and a submaximal preplasty was performed. The balloon was deflated and removed with wire left in place. The Xience Skypoint stent (4.0×33mm) was deployed across the lesion without complications. Follow-up runs demonstrated excellent apposition of the stent to the vessel wall

without in-stent stenosis. There was no delay in the vertebrobasilar system with excellent opacification of the vessels. Postprocedure angiography demonstrated no evidence of thrombus within the right VA. On post-operative day 1 (POD1), patient developed a mild hematoma on the right upper extremities (RUE). There were no other neurological complications otherwise.

Case 2

An adult patient with a critical right internal carotid stenosis (ICA) in the distal petrous portion of the artery beyond the cervical segment of the petrous segment. Patient was referred by their cardiologist following a history of recurrent strokes despite DAPT (aspirin+clopidogrel). Origin of the stroke was believed to be from atrial arrhythmias. However, the patient continued to have strokes despite anticoagulation therapy and closure of the appendages which prompted further evaluation. CTA performed 2 months prior procedure showed near-total occlusion of the right ICA just inferior to the horizontal segment of the skull base level. Pre-operation diagnostic angiogram confirmed the CTA finding, therefore, the patient was planned for right ICA stent placement for treatment of ICAD (figure 2).

For this procedure, patient was placed under conscious sedation. A 6-French 23cm sheath was placed under ultrasound guidance for a trans-radial approach. A RIST (Medtronic, Minneapolis, Minnesota, USA) catheter was

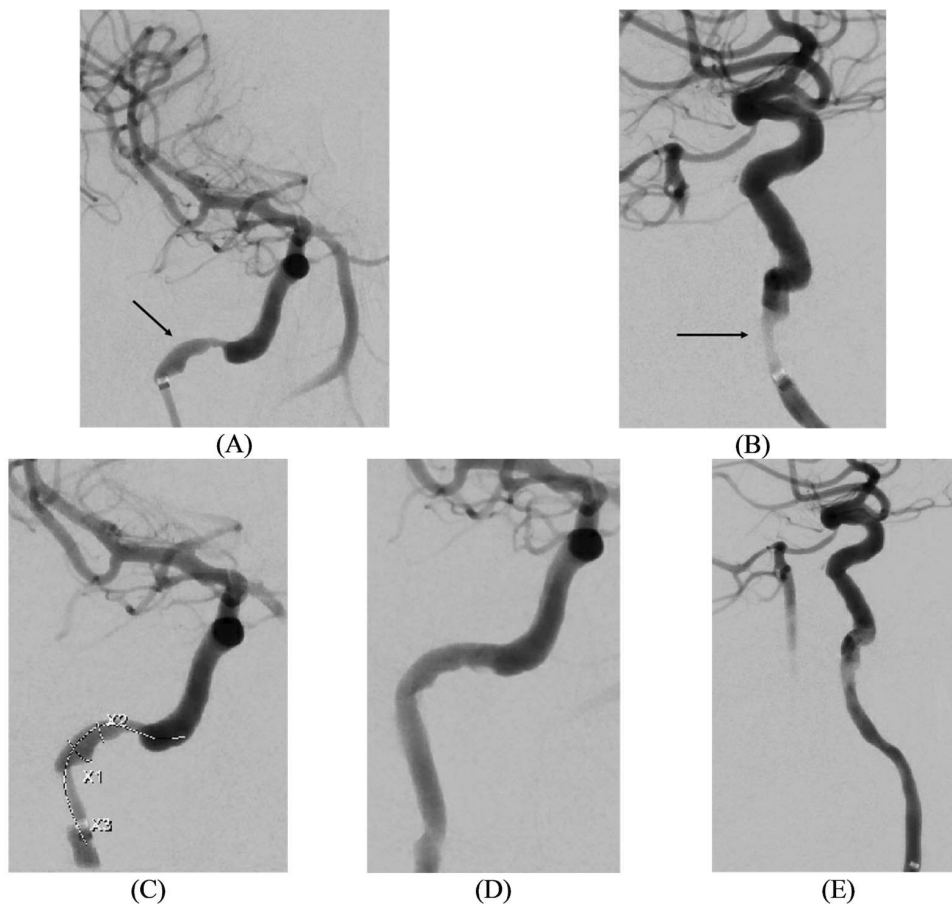


Figure 2 Adult patient with critical stenosis of the right internal carotid stenosis (ICA) in the distal petrous segment. (A) Anterior-posterior (AP) view of the right ICA with petrous stenosis. (B) Lateral view of the right ICA with petrous stenosis. (C) AP view of the right ICA with measurements for stent placement. (D) AP view of the right ICA after stent deployment. (E) Lateral view of the right ICA after stent deployment.

advanced into the prepetrous segment of right ICA. A 0.014 ASAHI Prowater guidewire was then used to cross the atherosclerotic lesion and placed in distal middle cerebral artery (MCA). The 0.014 wire was used to advance the Xience Skypoint stent, which was deployed without complications. The patient was then transferred out of the angiographic suite at their preprocedural neurological baseline and discharged at POD2.

Case 3

An adult patient with a prior history of strokes in the left MCA had undergone intracranial submaximal balloon angioplasty of the left ICA and was started on DAPT (aspirin+ticagrelor) 6 months prior. During this period, the patient presented numerous times to the ED with recurrent TIA. The patient's most common complaints were right-sided weakness (x4) and headache (x2). The patient's follow-up CTA after angioplasty showed severe narrowing of the left ICA due to diffuse calcified atherosclerosis. Pre-operative diagnostic angiogram showed severe narrowing of the left supraclinoid ICA; therefore, the patient was selected for left supraclinoid ICA stent placement (figure 3).

For this procedure, the patient was placed under conscious sedation. An 8-French sheath was placed under

ultrasound guidance, for right common femoral artery approach. A Walrus Balloon Guide Catheter (Q'Apel Medical, Fremont, California, USA) was advanced over a 0.35 angled glide wire to the left ICA. A coronary balloon guide was used to mount the Xience Skypoint stent, which was advanced across the lesion over a 0.014 ASAHI Prowater guidewire. The stent was deployed to nominal pressure and follow-up runs indicated increase flow to the MCA candelabra. Patient recovered strength on their right side on post-operative check and was discharged without complaints on POD1.

DISCUSSION

EES have been used with success in PCI for coronary artery disease. In a randomized study by Yamaji *et al*, researchers looked at different variables to compare polymer sirolimus-eluting stents to durable polymer EES (DP-EES) for PCI.¹⁶ The study reported that out of 2260 DP-EES implantation procedure attempts, only 1 failed.¹⁶ In addition, the restenosis rate including in-stent restenosis for DP-EES was 4.3% at the 1-year end point.¹⁶ Comparing it with the Wingspan stent which is currently approved by the FDA for treatment of symptomatic

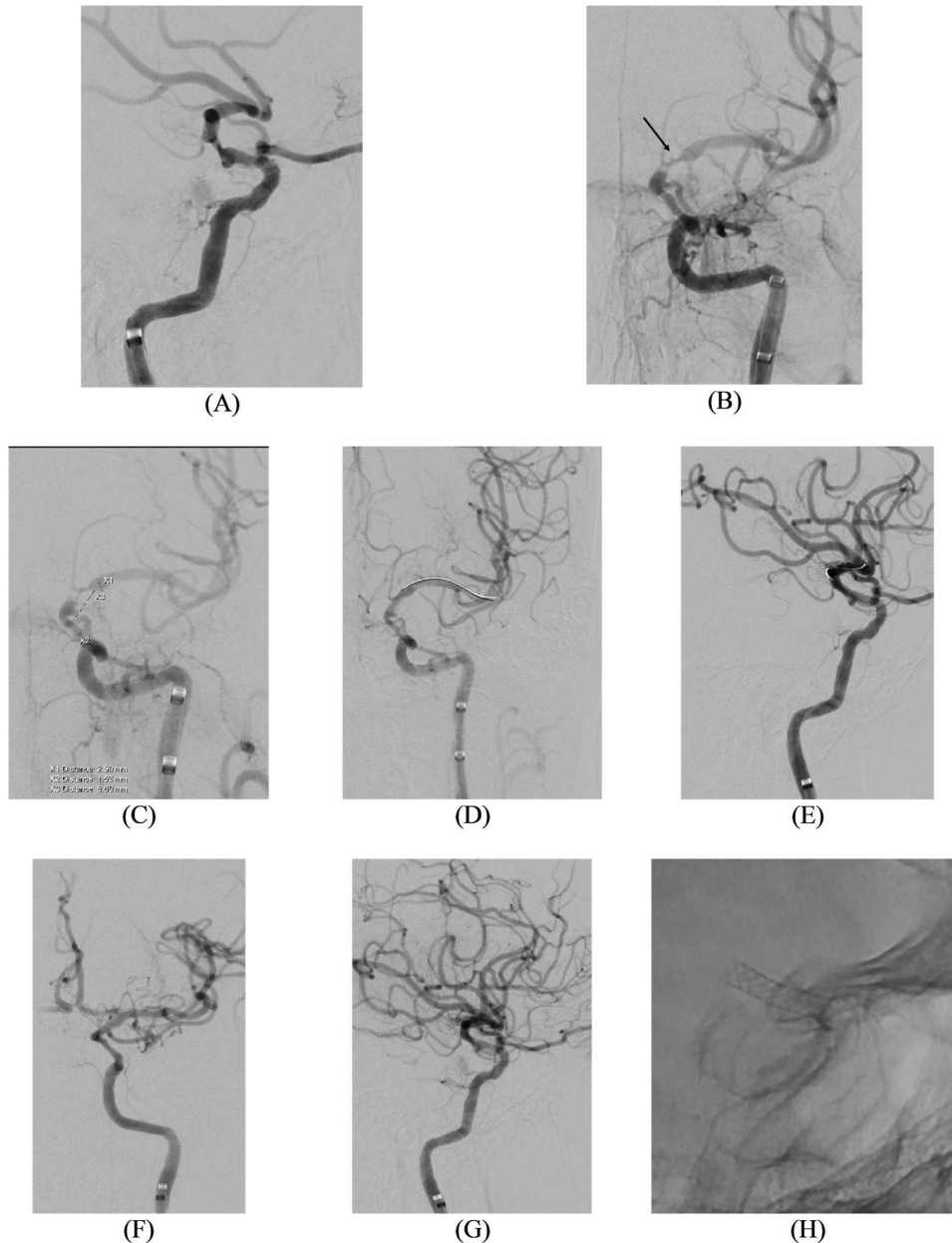


Figure 3 Adult patient with left supraclinoid internal carotid stenosis (ICA) stenosis. (A) Lateral view of left ICA with catheter in the prepetrous segment. (B) Anterior-posterior (AP) view of the left ICA with M1 stenosis and minimal filling of left anterior cerebral artery (ACA). (C) AP view of the left ICA with measurements for stent placement, X1=distal landing zone, X2=proximal landing zone, X3=stenosis distance. (D) AP view of the left ICA after stent deployment. (E) Lateral view of the left ICA after stent deployment. (F) AP view of the left ICA, with robust ACA filling and improved M1 stenosis after stent deployment. (G) Lateral view of the left ICA after stent deployment. (H) Lateral view of left ICA after stent deployment.

ICAD,¹⁷ EES have shown lower risk of restenosis. In the Wingspan One-year Vascular Events and Neurologic Outcomes, the restenosis rate of patients with Wingspan stents was 17.6%¹⁸ after 1 year.

Of the three patients implanted with the Xience Skypoint EES, only one suffered postprocedural complications. In that case, the patient developed a small RUE hematoma that resolved before discharge. There were no neurological complications otherwise.

The Xience Skypoint stent also has procedural advantages compared with other coronary DES used for neurointerventional procedures. The technique used in

this study required a biaxial system composed of a guide catheter and a coronary wire. Benefits of this technique include a lower risk of vessel manipulation and damage, less time under anesthesia due to shorter duration of the procedure, and less risk of kidney injuries due to contrast use. While intermediate catheters provide more support to devices and allow them to get around vessels easier, they come with an increased procedural cost. They also increase the length of the procedures, and the time patients must be under anesthesia because they require proper placement and positioning. In our experience, the Xience Skypoint stent was effectively

deployed without an intermediate catheter unlike other stents like the Resolute Onyx DES (Medtronic) that have shown success in ICAD treatment.¹⁷ The fact that intermediate catheters are not needed for the stent deployment means a reduction in cost and possibly the time of procedure for patients. Moreover, we demonstrate that the Xience Skypoint stent can be deployed using trans-radial, trans-ulnar, and trans-femoral access sites. For neurointerventional procedures, the trans-radial approach resulted in lower odds of complication than the trans-femoral approach.¹⁹ While there have not been many studies comparing trans-ulnar with trans-radial approach, a trans-ulnar approach is described as an alternative to trans-radial access.²⁰ In randomized studies for coronary interventions, complication risks using trans-ulnar access were found to be close to trans-radial access.^{21 22} Therefore, success in deploying the Xience Skypoint using three different approaches demonstrate the stent's flexibility, which gives providers the ability to perform their cases in a way that will be most beneficial to their patients.

This study has numerous limitations including the patient selection, number of patients, and its retrospective nature. Our goal was not to report on long-term vascular and neurological complications, but mainly to present the technical feasibility of deploying the Xience Skypoint EES for the treatment of intracranial atherosclerotic diseases. We believe that more studies are needed to assess short-term and long-term effects of this stent in ICAD treatment given its promises.

Twitter Nangorgo Jean Oumar Coulibaly @OumarJCoul and Hakeem J Shakir @HakeemShakirMD

Contributors NJOC reviewed, wrote, and formatted the manuscript. GLE collected figures from the patient's chart and wrote the technical parts of each case. HS reviewed the document and provided feedback and corrections. UB and BH were part of the idea development process and/or assisted during the procedures. HS proposed the idea, performed the procedure on the patients, reviewed the manuscript and is guarantor for this manuscript.

Funding The authors have not declared a specific grant for this research from any funding agency in the public, commercial or not-for-profit sectors.

Competing interests UB: honoraria from Abbott, AstraZeneca, Amgen, and Boston Scientific.

Patient consent for publication Not applicable.

Ethics approval This study only included reports from three patients, therefore did not meet criteria for an IRB. Participants gave consent to receive the procedure. The manuscript and study were conducted retrospectively after the procedures have been performed. In addition, the study only details the technical aspect of the procedure without including any personal or identifiable patient information.

Provenance and peer review Not commissioned; externally peer reviewed.

Data availability statement No data are available.

Open access This is an open access article distributed in accordance with the Creative Commons Attribution Non Commercial (CC BY-NC 4.0) license, which permits others to distribute, remix, adapt, build upon this work non-commercially, and license their derivative works on different terms, provided the original work is properly cited, appropriate credit is given, any changes made indicated, and the use is non-commercial. See: <http://creativecommons.org/licenses/by-nc/4.0/>.

ORCID iD

Nangorgo Jean Oumar Coulibaly <http://orcid.org/0000-0002-2674-2956>

REFERENCES

- 1 Caplan LR, Hennerici M. Impaired clearance of emboli (washout) is an important link between hypoperfusion, embolism, and ischemic stroke. *Arch Neurol* 1998;55:1475–82.
- 2 Mazighi M, Labreuche J, Gongora-Rivera F, *et al.* Autopsy prevalence of intracranial atherosclerosis in patients with fatal stroke. *Stroke* 2008;39:1142–7.
- 3 Chimowitz MI, Lynn MJ, Howlett-Smith H, *et al.* Comparison of warfarin and aspirin for symptomatic intracranial arterial stenosis. *N Engl J Med* 2005;352:1305–16.
- 4 Chimowitz MI, Lynn MJ, Derdeyn CP, *et al.* Stenting versus aggressive medical therapy for intracranial arterial stenosis. *N Engl J Med* 2011;365:993–1003.
- 5 Zaidat OO, Fitzsimmons B-F, Woodward BK, *et al.* Effect of a balloon-expandable intracranial stent vs medical therapy on risk of stroke in patients with symptomatic intracranial stenosis. *JAMA* 2015;313:1240.
- 6 Song L, Li J, Gu Y, *et al.* Drug-Eluting vs. bare metal stents for symptomatic vertebral artery stenosis. *J Endovasc Ther* 2012;19:231–8.
- 7 Palmerini T, Biondi-Zoccai G, Della Riva D, *et al.* Stent thrombosis with drug-eluting stents: is the paradigm shifting? *J Am Coll Cardiol* 2013;62:S0735–1097(13)04123–5:1915–21..
- 8 Camenzind E, Steg PG, Wijns W. Stent thrombosis late after implantation of first-generation drug-eluting stents: a cause for concern. *Circulation* 2007;115:1440–55.
- 9 Stone GW, Ellis SG, Colombo A, *et al.* Offsetting impact of thrombosis and restenosis on the occurrence of death and myocardial infarction after paclitaxel-eluting and bare metal stent implantation. *Circulation* 2007;115:2842–7.
- 10 Park KW, Kang S-H, Velders MA, *et al.* Safety and efficacy of everolimus- versus sirolimus-eluting stents: a systematic review and meta-analysis of 11 randomized trials. *American Heart Journal* 2013;165:241–250.
- 11 Stone GW, Rizvi A, Newman W, *et al.* Everolimus-Eluting versus paclitaxel-eluting stents in coronary artery disease. *N Engl J Med* 2010;362:1663–74.
- 12 Xience Everolimus Eluting Coronary Stent System: Patient Information. Guide: Abbott, 2021.
- 13 Sheiban I, Villata G, Bollati M, *et al.* Next-Generation drug-eluting stents in coronary artery disease: focus on everolimus-eluting stent (Xience V®). *Vasc Health Risk Manag* 2008;4:31–8.
- 14 Mishra S, Bahl VK. Curriculum in cath lab: coronary hardware -- Part II. guidewire selection for coronary angioplasty. *Indian Heart J* 2009;61:178–85.
- 15 Saeed B, Banerjee S, Brilakis ES. Percutaneous coronary intervention in tortuous coronary arteries: associated complications and strategies to improve success. *Journal of Interventional Cardiology* 2008;21:504–11. 10.1111/j.1540-8183.2008.00374.x Available: <http://blackwell-synergy.com/doi/abs/10.1111/joic.2008.21.issue-6>
- 16 Yamaji K, Zanchin T, Zanchin C, *et al.* Unselected use of ultrathin strut biodegradable polymer sirolimus-eluting stent versus durable polymer everolimus-eluting stent for coronary revascularization. *Circ Cardiovasc Interv* 2018;11:e006741.
- 17 White TG, Shah KA, Koul P, *et al.* n.d. The resolute onyx drug eluting stent for neurointervention: a technical series. *Interv Neuroradiol*:159101992210843.
- 18 Alexander MJ, Zauner A, Gupta R, *et al.* The WOVEN trial: Wingspan one-year vascular events and neurologic outcomes. *J NeuroIntervent Surg* 2021;13:307–10.
- 19 Catapano JS, Ducruet AF, Nguyen CL, *et al.* Propensity-adjusted comparative analysis of radial versus femoral access for neurointerventional treatments. *Neurosurg* 2021;88:E505–9.
- 20 Dossani RH, Waqas M, Tso MK, *et al.* Safety and feasibility of ulnar artery access for neuroangiography and neurointervention: a case series. *J NeuroIntervent Surg* 2021;13:109–13.
- 21 Sattur S, Singh M, Kaluski E. Trans-ulnar catheterization and coronary interventions: from technique to outcomes. *Cardiovasc Revasc Med* 2017;18:S1553–8389(17)30015–5:299–303..
- 22 Shafiq M, Mahmoud HB, Fanous ML. Percutaneous trans-ulnar versus trans-radial arterial approach for coronary angiography and angioplasty, a preliminary experience at an Egyptian cardiology center. *Egypt Heart J* 2020;72:60.